

Lead Induced Infertility in Swiss Mice and Role of Antioxidants

Ragini Sharma, Nazera Qureshi, Sheetal Mogra and Khushbu Panwar

Environmental and Developmental Toxicology Research Laboratory, Department of Zoology, University College of Science, Mohanlal Sukhadia University, Udaipur (Rajasthan) 313001 India

Corresponding author: nazeraqureshi@yahoo.com, taurasragini@yahoo.com

Abstract:

In the present study, effects of lead toxicity on fertility of female Swiss mice have been investigated. Implantation sites, litter size, body weight of pups and histopathology of ovary were investigated. Lead toxicity was induced by lead acetate given orally for 3 months. The treatment of lead poisoning through chelating agents can remove essential elements, resulting in kidney damage. Oxidative damage associated with presence of lead has been illustrated as one possible mechanism involved in lead toxicity which suggests that antioxidant (vitamin C and E) might play a role in the treatment of lead induced infertility. The role of vitamins in treating/preventing chronic reproductive lead toxicity in animals is receiving wide attention. Therefore, along with above study, therapeutic effects of ascorbic acid and alpha-tocopherol on lead induced reproductive toxicity have also investigated. In lead treated group, there was decline in fertility, less number of implantation sites, decreased in litter size, decreased in body weight of pups and damage in ovary was observed. With supplementation of ascorbic acid along with lead witch induced in fertility, implantations were visible in uterus but no litter was born. Ascorbic acid could not prevent ovary damage. In lead+ vitamin E and lead+ vitamin C+ vitamin E treated groups there was improved fertility outcomes, increase in number of implantation sites, body weight of pups were also increased and ovaries were protected. Only vitamin C and E treated groups were nearly similar to control.

Keyword: Lead toxicity, Fertility, Oxidative stress, Ascorbic acid, Alpha-tocopherol.

1.0 Introduction:

Lead is highly toxic to humans, with the deleterious effects on the haemopoietic, nervous, reproductive systems and the urinary tract. Lead has been shown to cross the placenta during pregnancy and has been associated with intrauterine death, prematurity and low birth weight (Papanikolaou *et al.* 2005). Environmental lead toxicity is an old but persistent public health problem throughout the world and children are more susceptible to lead than adults (Ahmed and Siddiqui, 2007). Lead poisoning among pregnant women is a significant public health problem, as it affects development (Katharine Weizsaecker, 2003). The development of a child begins in uterus and continues following birth, thus, both of these time frames must be examined as possible periods of lead intoxication. Reproductive toxicity, which can be defined as the adverse effect of chemicals, lead being one that can affect the gonadal structure and functions, can cause alterations in fertility and impaired gamete function (Hu, 1998; Timbrell, 1995). Lead poisoning causes reduced fertility, miscarriages and stillbirths since antiquity (Bell and Thomas, 1980). Gestational lead

exposure has an adverse effect on development; with effects that may be most pronounced during the first trimester (Mogra, *et al.* 2009). During development, the fetus is at the mercy of its mother. If the mother has high blood lead levels during pregnancy, the developing fetus will have the same. Lead freely crosses the placenta consequently; gestational lead poisoning is not only harmful to the women but also to the developing fetus (Shannon *et al.*, 2003).

Implantation is an intricately timed event necessary in the process of viviparous birth that allows mammals to nourish and protect their young during early development (Kevin and Franceso, 2004). Implantation is the process that leads from blastocyst attachment to its embedding in the uterine wall. It is widely believed that failure of implantation is a common cause of pregnancy loss. Toxic agents can interfere directly with the process of implantation and therefore may account for unexplained implantation failures (Genbacevet *et al.*, 1993). Classical signs of lead poisoning for pregnant women are spontaneous abortion. Manifestation in the fetus and newborn

include prematurity, fetal hypotrophy and malformations (Klein *et al.*, 1994). Lead is one of the strong teratogens which cause most of its congenital effect at the time of organogenesis during embryonic development. The ovarian follicle is the functional unit of the ovary. It contains the oocyte that may eventually ovulate, undergo fertilization and form an embryo. It also provides the steroid and protein hormones required for maintenance of the ovarian cycle, the secondary sex characteristics and preparation of the uterus for implantation (Findlay *et al.*, 2009). ROS affect multiple physiological processes from oocyte maturation to fertilization. Ovulation-induced oxidative base damage to DNA of the ovarian epithelium can be prevented by antioxidant (Agarwalet *al.* 2005). Antioxidative properties of vitamin E is believed to prevent reproductive disease associated with oxidative stress (Brigelius-Floheet *al.* 2002). Vitamin C was shown to act as a chain breaking scavenger for peroxy radicals and also to act as synergist with vitamin E (Stocker and Feri, 1991). Ascorbic acid may also prevent gametes from damage by free radicals during reproduction and fertilization.

2.0 Materials and Methods:

Inbred, healthy, female Swiss mice in the age group of 5-6 weeks, with 22-28 gm body weight were used for the experiment and divided in to VII groups containing ten animals in each. These groups were treated orally with (160mg/kg/day) dose of lead acetate, vitamin C (200mg/ kg/day) and vitamin E (160mg/kg/day) for 3 months according to following schedule:

Group I (Control group) - This group served as control, and was given distilled water through Canula.

Group II (L) - Treated with lead acetate (160mg/kg/day).

Group III (LC) - Treated with lead acetate + vitamin C (160 + 200mg/kg/day, respectively).

Group IV (LE) - Given lead acetate + vitamin E (160 + 160mg/kg/day, respectively).

Group V (LCE) - Treated with lead acetate + vitamin C + vitamin E (160+200+160mg/kg/day, respectively).

Group VI (Only Vitamin C) - Given only vitamin C (200mg/kg/day).

Group VII (Only Vitamin E) - Given only vitamin E (160mg/kg/day).

In each group there were total 12 animals (10 females, 2 males). Total VII group were selected for this study. In all the groups after two months, male was introduced in the breeding cages. Each animal of the group was checked in the morning

for vaginal plug. The animals showing vaginal plugs were separated marked and put for further observations. After termination of the experiment animals were sacrificed by cervical dislocation. Immediately after sacrificing animals, ovaries were fixed in Bouin's fixative for histopathological observations (Drury and Wallington, 1967). Uterus were immersed in 2% Na OH for 1 min. to observe implantation sites and resorption.

3.0 Results and Discussion:

3.1 Group I (Control):

In this group after 19-20 days females delivered pups.

All the pups were healthy and normal.

Litter size 8-10 animal.

In this group all the follicles were normal in structure and distribution pattern of various components. Germinal epithelium (Ge), cortex (C) and inner medullary region (M) were apparent.

3.2 Group II (Lead treated):

In lead treated group the number of implantation sites was less than controls.

The number of pups was less than number of implantation sites.

Numbers of resorption were increased.

Reduced litter size.

Body weight was reduced.

Young ones were eaten by mothers.

In this group animals showed damaging pattern in this structure and distribution of various follicles. There was evident damage in germinal epithelium, cortex and inner medullary region.

3.3 Group III (Lead + Vitamin C) and Group V (Lead + Vitamin C + Vitamin E):

In lead with vitamin C treated group pregnancies were continued for approximately thirteen days but may be due to resorption, the gestation period was not completed. In lead + vitamin C +vitamin E treated group the pregnancy continued till mid gestation period and resorption occur after mid gestation period.

No parturition was occurred.

No litters were born.

Administration of lead with vitamin C induced the toxic effects in the ovary, however appreciable protection was also observed. Germinal epithelium, cortex and inner medullary regions were also protected. Ovary of lead treated animals, with co-administration of vitamin C and vitamin E showed minor protection in germinal epithelium, cortex and inner medullary region.

Both damage as well as protection can be seen in all components.

3.4 Group IV (Lead + Vitamin E)-

Implantation sites with few resorption.
Litter size was small.
Pups were healthy.
Body weight of pups was less than control.
The ovary of the mice treated with vitamin E along with lead showed more protection in comparison to lead + vitamin C treated animals. Germinal

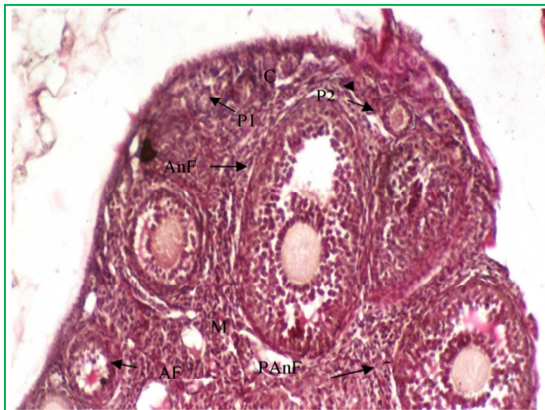epithelium, cortex and inner medullary regions were preserved.

3.5 Group VI (Only Vitamin C) and Group VII (Only Vitamin E):

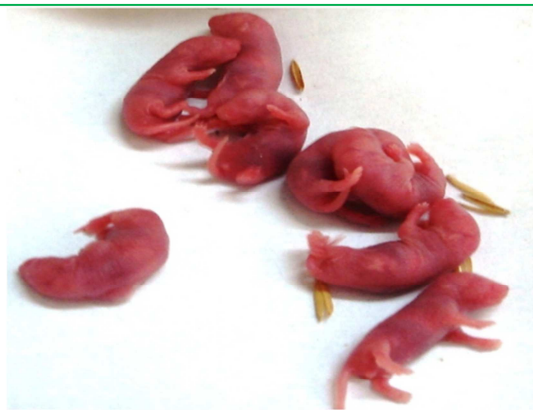Female delivered the pups,
Pups were healthy.
Litter size was normal.
Body weight of pups was less than controls.
In these group follicles were normal in their structure and distribution pattern of various components in ovary was also normal.

S.No	Groups	No. of Animals	Treatment	No. of pregnant female after 2 months	Littersize (Number of pups)	Average weight of single pup
1.	Group I	12 10(Female) + 2(Male)	Control	6+1	8-10	1.78 gm/each
2.	Group II	12	Only Lead	3 Preg. 3 Px	4-6	Abnormal
3.	Group III	12	Lead+VitaminC	2 Preg. 2 Px	-	-
4.	Group IV	12	Lead+VitaminE	4Preg. → 2 Px	6-7	1.22 gm/each
5.	Group V	12	Lead+VitaminC+VitaminE	3Preg→ 2Px	-	-
6.	Group VI	12	Only Vitamin C	6Preg→	8-9	1.25 gm/each
7.	Group VII	12	Only Vitamin E	6Preg→	9-10	1.27 gm/each

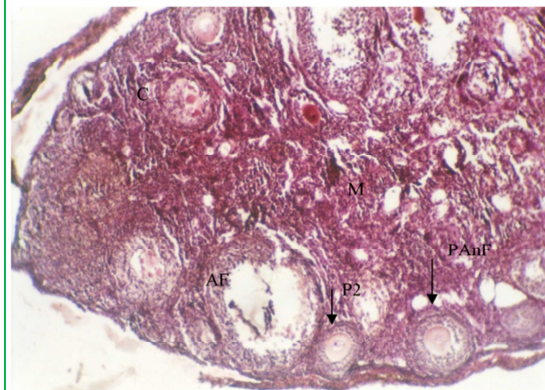
Px: No pregnancy
Preg→: Pregnancy persist



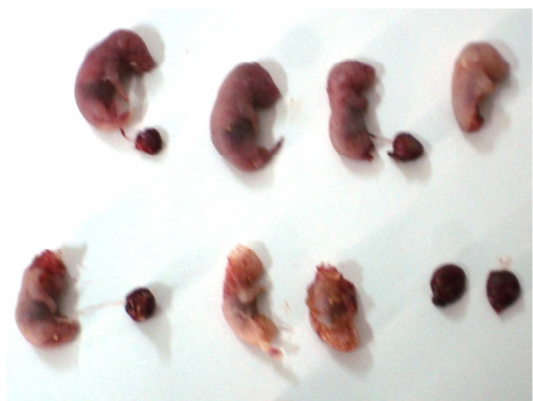Ovary of control group animals showing normal structure and distribution pattern of various ovary components. Different types of developing follicles, i.e. primordial(P1), primary(P2),preantral follicles(PAnF),antral follicles(AnF) and atretic follicles(AF) are normal in state.Cortex(C) and inner medullary region (M) are also visible in normal state. X 100



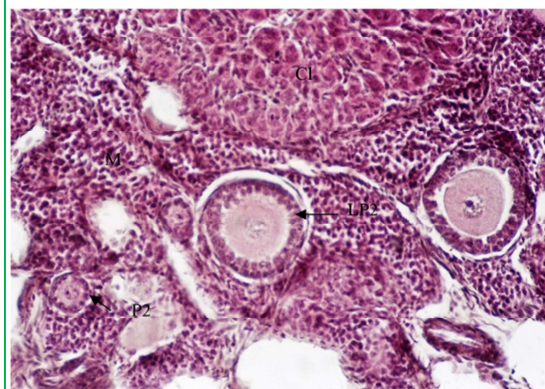
In control group pups showing normal morphological appearance and body weight.



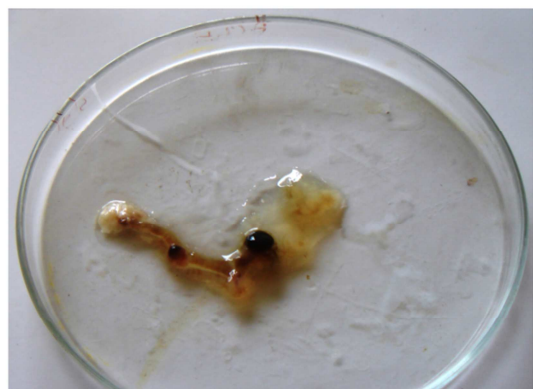A lead treated(160mg/kg/day) ovary showing damaging pattern in its structure and distribution of various components. Different types of developing follicles, i.e. primary(P2), preantral follicles (PAnF) and atretic follicles (AF) are not apparent in normal state. This Fig. shows damage in cortex (C) and inner medullary region (M). The area of the medullary region (M) is not compact. X 100



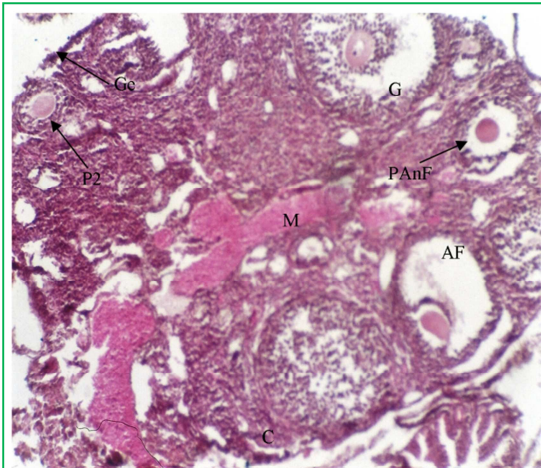
The pups of lead treated group showing abnormal development and reduced body weight.



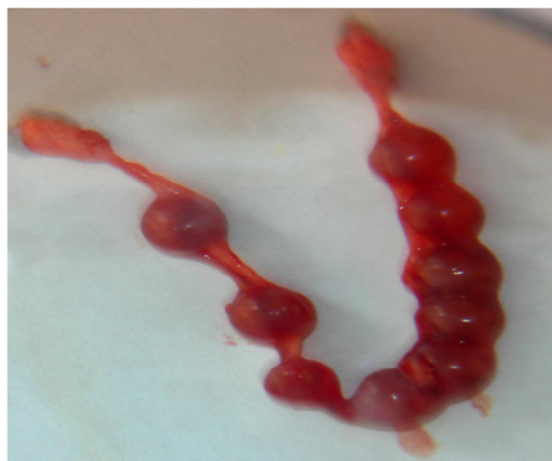Ovary of L+C+E treated group showing protected histological architecture, quite similar to the control group. Almost no damage is seen in inner medullary region (M). This Fig. showing protection in different types of developing follicles, i.e. primary follicles (P2) and late primary follicles (LP2). In this group showing altered structure of corpus luteum (C1). The granulosa lutein cells (GLC) and theca lutein cells(TLC) are not distributed evenly and they cannot be distinguished separately. X 100.



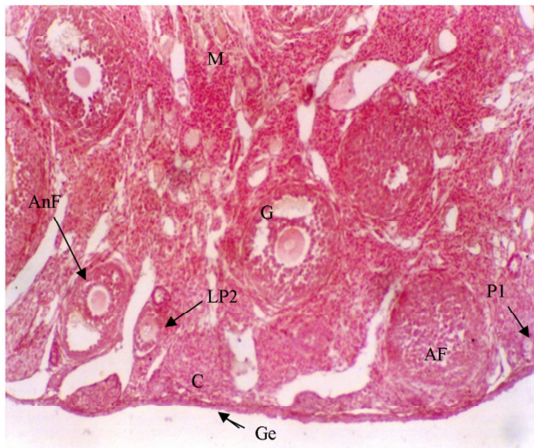
Uterus of L+C+E treated group showing resorption.



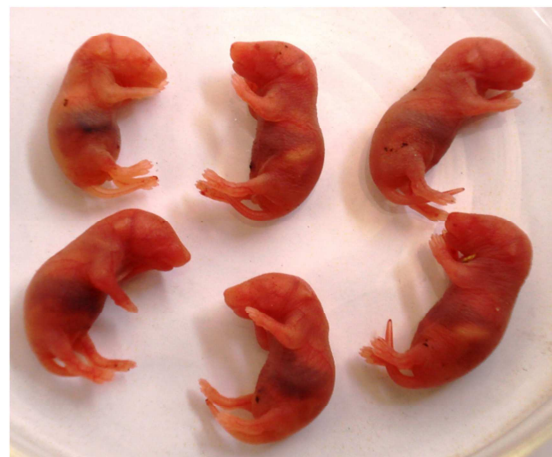Ovary treated with lead acetate and vitamin C showing protection as well as damage in overall ovary structure. Germinal epithelium (Ge), cortex (C) and inner medullary region (M), all are protected to a lesser degree. This Fig. shows primary (P2), atretic (AF) and graafian follicles (G) are in normal state and few damaged preantral (PAnF) and atretic follicles (AF). X 100



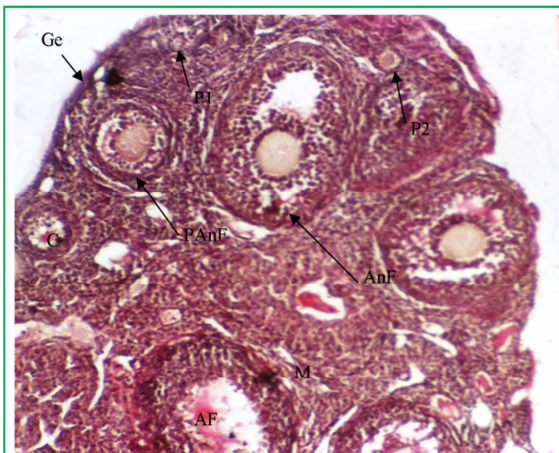
Lead + Vitamin C treated group showing normal implants on 12-13 day in uterus of female Swiss mice. In this group partition did not occur.



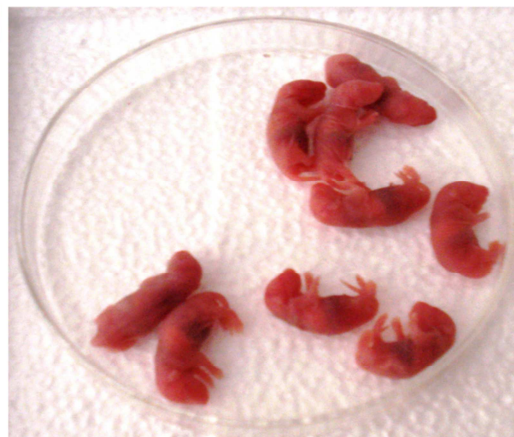
Ovary treated with lead + vitamin E shows more protection in histological architecture in comparison to lead + Vitamin C treated group. Germinal epithelium (Ge), cortex (C) and inner medullary region (M) are better state. Different types of developing follicles, i.e. primordial (P1), late primary (LP2), antral (AnF), graafian (G) and atretic follicles (AF) are also present in normal state. X 100.



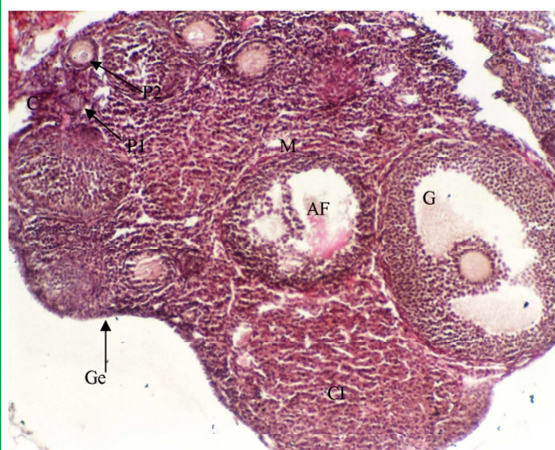In lead + Vitamin E treated group pups showing normal development and body weight.



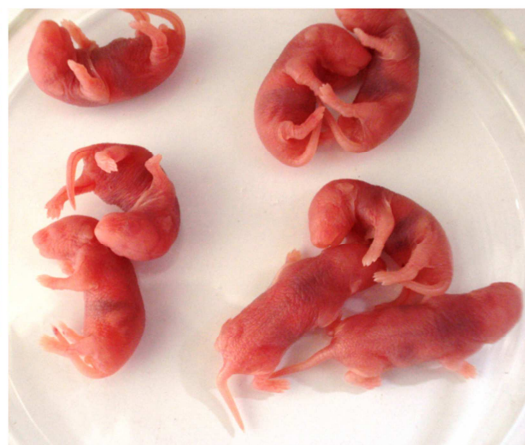Ovary of vitamin C treated mice showing normal structure and distribution pattern of various ovary components. This shows germinal epithelium (Ge), cortex (C) and inner medullary region (M) in normal state. Different types of developing follicles, i.e. primordial (P1), primary (P2), preantral (PANF), antral (AnF) and atretic follicles (AF) are also visible in normal state. X 100



Only vitamin C treated group pups showing normal morphological appearance and reduced body weight.



Vitamin E treated ovary showing normal structure and distribution pattern of various ovary components. Germinal epithelium (Ge), cortex (C) and inner medullary region (M) are in normal state. Different types of developing follicles, i.e. primordial (P1), primary (P2), graafian (G) and atretic follicles (AF) are in normal state. This Fig. also showing normal structure of corpus luteum (Cl). X 100



Only vitamin E treated group pups showing normal morphological appearance and increased body weight as compared to only vitamin C treated group.

The present study shows that exposure of lead caused post implantation loss in female Swiss mice because it might be possible that metal are directly bind to critical membrane sites and/ or intracellular ligands, including protein and nucleic acid, that may trigger inhibition of development

and death prior to metal-associated oxidative damage. It seems that a deficiency in the progesterone levels is directly implied in this inhibition (Jacquet, 1976). Lead treatment was found to reduce significantly the incidence of pregnancies and increase the post implantation

loss in the pregnant females (Jacquet, 1975). Previously, Tang and Zhu (2003) also noted that occupational lead exposure of female workers could lead to the impairment of the functions of reproductive system.

In the present investigation, lead treated females showed reduced number of pregnancies, small litter size and decreased body weight with spontaneous abortion. Wide (1985) studied the exposure to lead at a time of early organogenesis, caused fertility decrease by interfering with the development of the female germ cells. The effects of 200 and 400 ppm lead acetate in drinking water on reproduction and development as well as on renal and hepatic parameters of rats at different life stages, from gestation to 3 months post weaning were studied by Teijonet *al.* (2006). They concluded a dose dependent effect on reproduction with variations in the number of births and in pups' weight. Hamilton *et al.* (1994) reported that dietary calcium and lead exposure influenced pup body weight and lengths. The lead induced reduction in body weight and lengths was greatest in pups of dams fed with the low calcium diet, probably as a result of the greater organ lead accumulation and toxicity caused by this diet and/or the reduced weight gain of the dams during pregnancy. The later may be due to the result of the reduced food intake that has been associated with lead toxicity. Results suggest that litter size, gender and fetal position in the uterus can influence fetal weight in rats. In the present investigation, animals treated with lead showed vaginal plug but no pregnancies were observed in these females and body weights of females were also decreased. Animals treated with lead revealed reduce fertility as compared to control group animals, the maternal transfer of lead during gestation are very efficient. It is also apparent that lead uptake is greater during the fetal/ neonatal period. Gestational exposure adversely affects the postnatal development of pups. It reduces the pup body weight, length and delays their physical development.

The pathogenesis of adverse pregnancy outcomes including preeclampsia and fetal growth restriction (Myatt and Cui, 2004) and a number of neonatal outcomes (Saugsted, 2001) have been showed to be associated with oxidative stress. Lead potentially induced oxidative stress and evidence was accumulating to support the role of oxidative stress in the pathophysiology of lead toxicity. It was capable of inducing oxidative damage to brain, heart, kidneys and reproductive organs. The

mechanisms for lead induced oxidative stress include, the effects of lead on membranes, DNA and antioxidant defense systems of cells (Vassalloet *al.* 2008). Antioxidant (vitamin C and E) might play a role in the treatment of lead induced infertility (Gureret *al.*, 2001). Naturally occurring antioxidants have been extensively studied for their capacity to protect organisms and cells from damage induced by oxygen reactive species (Cozziet *al.*, 1997). The role of vitamins in treating chronic lead toxicity in animals is receiving wide attention (Anitraand Frei, 1999). It had become clear that high to moderate doses of lead exposure induce generation of free radicals resulting in oxidative damage to critical biomolecules, lipids, proteins and DNA (Ahamedet *al.*, 2007). The present study indicates that, ovaries of treated group showed increased number of atretic follicles and congestion in stromal tissue, compared to controls. There was a dose dependent reduction in the number of follicles at different stages of maturation. It was also observed that ovarian physiology and rate of ovulation might also altered in females exposed to high lead level, because corpora lutea was rarely seen in the treated females.

From the findings of present study it is clear that the lead also affects the developing follicles but the extent of damage increases with time. Thecal cells may also be targets for heavy metal injury. Lead is known to disturb the normal profile of reproductive hormones in animals, both at hypothalamic pituitary and at the gonadal levels (Roniset *al.*, 1996; Roniset *al.*, 1998). Similarly Shirotaet *al.* (2003) and McMurryet *al.* (1995) noted that lead causes reduction in the number of primordial follicles and decrease the number of follicles that enter the growing phase. Lead adversely affects pituitary hypothalamus axis, and the balance of gonadotropin. From the present study it is clear that both the time of exposure and amount of teratogens affects the development process, but the mechanism through teratogens causing teratogenicity is very important. Lead toxicity leads to free radical damage via two separate, although related pathways: (i) the generation of reactive oxygen species (ROS), including hydroperoxides, singlet oxygen, and hydrogen peroxide and (ii) the direct depletion of antioxidant reserves. In any biological system, oxidative stress (OS) can arise as result of excessive production of free radicals. The oxidant status can influence early embryo development by modifying the key transcription factors (Dennerly, 2004). Another aspect which affects the

development may be hormonal imbalance. The reproductive axis is particularly sensitive to lead during specific developmental period. The mechanisms underlying this appear to involve lead actions on both LH release and gonadal function (Roniset *al.* 1998). The inhibition of implantation caused by lead seems to be due to mainly an action of this metal on the hormonal balance of the exposed mother (Jacquet, 1978). The implantation failure may be due to an effect of lead on uterine responsiveness to ovarian steroids (Wide, 1980).

Agarwal *et al.* (2005) reported that ROS (reactive oxygen species) affect multiple physiological processes from oocyte maturation to fertilization, embryo development and pregnancy. During the last 90, years since the discovery of vitamin E, research has focused on different properties of this molecule, the focus often depending on the specific techniques and scientific knowledge present at each time. Originally discovered as a dietary factor essential for reproduction in rats, vitamin E has revealed in the meantime many more important molecular properties, such as the scavenging of reactive oxygen and nitrogen species associated with many diseases (Zingg, 2007). In the present study, order of effectiveness of vitamins was found to be as follows: vitamin C plus vitamin E > vitamin E > vitamin C. In the present investigation lead and vitamins (vitamin C and E) revealed protective role on the reproduction of female Swiss mice. In lead + vitamin C treated group the animals showed vaginal plugs and the pregnancy were continued for approximately thirteen days but may be due to resorption, the gestation period was not completed and no litters were born.

In lead + vitamin E treated group, the animals showing vaginal plugs were separated, and young ones were born and they were healthy. In lead + vitamin C + vitamin E treated group, the animals exhibited vaginal plugs, in these females pregnancy continued till mid gestation period but parturition did not occur. In the present study the follicular growth and regression of atretic follicles were observed in control animals. Antral cavities with dead granulosa cells can be easily identified in ovaries of controls. But the dynamics of follicular growth and formation of atretic follicles were altered with the lead exposure. The lead exerts inhibitory effect on follicular growth but stimulates the atretic follicle formation. Evans *et al.* (1997) have shown that the ovarian hormones secreted by follicles may play an important role in the

regulation of FSH and follicular dynamics. The microscopical examination of ovary in the present study revealed that there was apparent damage and reduction in the number of primordial follicles while the number of atretic follicles increases markedly. From the findings of present study it is clear that the low levels of lead affects the follicle and the extent of damage increase with the concentration of lead.

In the present investigation lead treated animals showed reduced primary follicles, the granulosa cells gathered in the centre of the follicle and oocyte was not apparent. The reduction in the number of granulosa cells, and apparent shrinkage in these cells were also observed. In most of the follicles the regular structure of granulosa cells altered. The degeneration in granulosa cells was apparent in all developing follicles. Zona pellucida was also less obvious as compared to controls. Bedaiwy and Falcone (2003) reported that the control of ovarian stromal cells and germ cell function is a diverse paradigm and oxidative stress may be one of the modulators of ovarian germ cell and stromal cell physiology. The hypothalamic pituitary gonadal axis present in females, GnRH release and the timing of changes in the relative levels of the major gonadotropin, LH and FSH are linked to ovarian follicular cycle. Disruptions at the gonad, pituitary or hypothalamus during the preovulatory stage can cause failure of folliculogenesis and there will be no ovulation for the affected cycle. It has been demonstrated that LH stimulates follicular maturation and induces follicular atresia (Balasch and Fabregues, 2006). Recent study suggests that LH is also stimulant for early stages of follicular growth (Tajima *et al.*, 2007; Mori *et al.*, 2009). Lead not only exerts inhibitory effect on follicular growth but also stimulates the atretic follicle formation.

Reactive oxygen species can cause granulosa cell death and addition of ascorbic acid has been seen to reduce this damage (Tilly and Tilly, 1995). Luck *et al.* (1995) noted that ascorbic acid has long been associated with fertility, but no consistent study of its mechanisms of action in reproductive tissues has been made. Treatment with metal chelators is not recommendable due to their multiple side-effects. Prevention from the heavy metal sources and introducing antioxidant vitamins in regular diet is the only adequate treatment. Knnan and Flora (2004) also reported that co-administration of vitamin E or vitamin C may be useful in the restoration of altered biochemical variables. Since vitamin C works in cooperation with other

antioxidants, its administration in disease which are followed by oxidative stress is more effective when used in combined preparations. The treatment of antioxidant vitamin, like vitamin C and vitamin E were not completely ameliorating these damages produced by lead, but vitamin C and vitamin E individually gave positive results for body weight, body size and development of pups.

Kim *et al.* (2004) studied the Ischemic tissue damage in ovarian cortex and to evaluate the effectiveness of ascorbic acid and antioxidant to protect ovarian tissue from apoptosis. Murry *et al.* (2001) reported that ascorbic acid is necessary for remodeling the basement membrane during follicular growth and that the ability of follicles to uptake ascorbic acid confers an advantage in terms of granulosa cell survival. In the present investigation there was complete protection in all ovary components i.e. germinal epithelium, cortex and inner medullary region, in the ovary of the animals treated with lead, vitamin C and vitamin E. The lead and vitamins (Vitamin C and E) treated animals showed protection in primordial, primary, preantral and antral follicles. In these animals the number of graffian follicles were increased as well as number of granulosa cells were also increased. Qureshi *et al.* (2010) noted that lead toxicity induced histological alterations in the various components in the ovary and these changes were rebalanced with the administration of antioxidant vitamins. Brigelius-Floheet *et al.* (2002) reported that vitamin E is necessary for reproduction in female rats. Antioxidative properties of vitamin E is believed to prevent disease associated with oxidative stress. Stocker and Frei (1991) concluded that vitamin C donates a hydrogen atom to the vitamin E deliver phenolate radical thus regenerating its activity. Ascorbic acid also acts to protect membranes against peroxidation by enhancing the activity of alpha- tocopherol, the chief lipid soluble and chain breaking antioxidant. Ascorbic acid may also prevent gametes from damage by free radicals during reproduction and fertilization. Vitamin C removes not only the free radicals, as supported by a majority of recent investigations, but also the toxicity of lead or lead-induced oxidative damage from the human body (Tariq, 2007).

4.0 Conclusions:

We can conclude that the reactive oxygen species generated by lead is responsible for the ovarian dysfunction affecting the female reproduction, with the poor fertility outcomes and reduced body weight of dams and pups. The beneficial effects of

oral supplementation of antioxidants vitamins in ovarian dysfunction are also very promising. Future studies on animal models will provide novel information on the safely and effectiveness of antioxidant vitamins in improving the female fertility. Impaired oxidant / antioxidant balance be partially responsible for the toxic effects of lead. Antioxidants vitamin E+C plays an important role in abating many reproductive hazards of lead. Vitamins are capable of protecting the follicles at every stage of their development and in the improvement of various factors related to fertility.

References:

- 1) Papanikolaou, N.C., Hayzidaki, E.G., Belivanis, S., Tzanakakis, G.N. and Tsatsakis, A.M. (2005) :Lead toxicity update. *A brief review. MedSciMonit, Oct*; 11(10): RA 329-3.
- 2) Ahamed, M. and Siddiqui, M.K. (2007): Low level lead exposure and oxidative stress: current opinions. *ClinChimActa, Aug*; 383(1-2):57-64.
- 3) Katharina Weizsaecker, M.D. (2003): Lead toxicity during pregnancy. *Primary care update for OB/GYNS*, 10: 304-309.
- 4) Hu, H. (1998): Heavy metal poisoning. In : Fauci, A.S., Braunwald, E., Jsselbacher, K.J., Wilson, J.D., Martin, J.B., Kasper, D.L., Hauser, S.L., Longo, D.L. Eds. *Harrison's Principales of Internal Medicine*, 14 ed., New York:McGraw-Hill, p. 2564-2569.
- 5) Bell, J.U. and Thomas, J.A. (1980): Effects of lead on mammalian reproduction. In "Lead Toxicity". (RL Singhal and JA Thomas, eds.), pp.169-186. Urban & Schwarzenberg, Munich.
- 6) Mogra, S., Sharma, R. and Qureshi, N. (2009): Effects of meternal lead acetate exposure on prenatal development of Swiss albino mice. *Asian J. Environmental Sci.*, 4(2): 216-220.
- 7) Shannon, M. (2003): Severe lead poisoning in pregnancy. *Ambul. Pediatr.*, 3: 37-39.
- 8) Kevin, Y.L. and Francesco, J.D. (2004): Animals models of implantation. *Reproduction*, 128: 679-695.
- 9) Genbacev, O., White, T.E., Gavin, C.E. and Miller, R.K. (1993): Human trophoblast cultures: Models for implantation and periimplantation toxicology. *ReprodToxicol*, 7:75-94.
- 10) Klein, Y.L., Kaminsky, P., Barbe, F. and Due, M. (1994): Lead poisoning in pregnancy. *Press Med.*, 23:576-580.
- 11) Findlay, J.K., Kerr, J.B., Britt, K., Liew, S.H., Simpson, E.R., Rosairo, D. and Dewmmond (2009): Ovarian physiology: follicle

- development, oocyte and hormonal relationship. *Anim. Reprod.*, 6(1): 16-19.
- 12) Agarwal, A., Gupta, S. and Sharma, R.K. (2005): Role of oxidative stress in female reproduction. *ReprodBiolEndocrinol*, Jul 14; 3(1):28.
 - 13) Brigelius- Flohe, R., Kelly, F.J., Salonen, J.T., Neuzil, J., Zingg, J.M. and Azzi, A. (2002): The European perspective on vitamin E: current knowledge and futureresearch. *Am J Clin Nutr*, Oct; 76(4):703-16.
 - 14) Stocker, R. and Frei, B. (1991): Endogenous antioxidant defences in human blood plasma. In: *Oxidative Stress* (Sies, H. ed.), pp.213-243. Academic Press, London.
 - 15) Drury, R.A.B. and Wallington, E.A. (1967): Carleton's histological techniques. Oxford University Press: New York, Toronto.
 - 16) Jacquet, P. (1976): Effects of lead administration during pregnancy to C57BL mice. *C R Seances Soc. BiolFil.*, 170 : 1319-1322.
 - 17) Jacquet, P., Leonard, A. and Gerber, G.B. (1975): Embryonic death in mouse due to lead exposure. *Experientia*, 31: 1312-1313.
 - 18) Tang, N. and Zhu, Z.Q. (2003): Adverse reproductive effects in female workers of lead battery plants. *Internat. J. Occup. Med. Environ. Health*, 16(4): 359-361.
 - 19) Wide, M. (1985): Lead exposure on critical days of fetal life affects fertility in the female mouse. *Teratology, Dec.*, 32(3): 375-380.
 - 20) Teijon, C., Olmo, R., Blanco, D., Romero, A. and Teijon, J.M. (2006): Low doses of lead: effects on reproduction and development in rats. *Biol. Trace Elem Res, Summer*; 111 (1-3): 151-165.
 - 21) Hamilton. D., O'Flaherty, E.J., Ross, R., Shukla, R., Gartside, P.S. (1994): Structural equation modeling and nested ANOVA: effects of lead exposure on maternal and fetal growth in rats. *Environ Res* 64: 53-64.
 - 22) Myatt, L. and Cui, X. (2009): Oxidative stress in the placenta. *Histochem. Cell Biol.*, 122: 369-382.
 - 23) Saugsted, O.D. (2001): Update on oxygen radical disease in neonatology. *CurrOpinObstet 542 Gynacol*, 13:147.24.
 - 24) Vassallo, D.V., Lebach, E.C., Moreira, C.M., Wiggers, G.A. and Stefanon, I. (2008): Lead reduces tension development and the myosin ATPasa activity of the rat right ventricular myocardium. *Braz. J. Med. Biol. Res.*; 41(9): 789-795.
 - 25) Gurer, H., Ozygunes, H., Saygin, E. and Erca, I. N. (2001): Antioxidant effects of taurin against lead- induced oxidative stress. *Archives of Environmental Contamination and Toxicology*, 41(4): 379-402.
 - 26) Cozzi, R., Ricordy, R., Aglitti, T., Gatta, V., Perticone, P. and De Salvia, R. (1997): Ascorbic acid and Beta – carotene as modulators of oxidative damage. *Carcinogenesis*, 18(1): 223-228.
 - 27) Anitra, C.C. and Feri, B.(1999): Toward a new recommended dietary allowance for vitamin C based on antioxidant and health effects in humans. *American J. Clinical Nutrition*, 69(6): 1086-1107.
 - 28) Ahmed, M. and Siddiqui, M. K. (2007): Low level lead exposure and oxidative stress: current opinions. *ClinChimActa, Aug*; 383 (1-2): 57-64.
 - 29) Ronis, M.J., Badger, M.T., Shema, S.J., et al. (1996): Reproductive toxicity and growth effects in rats exposed to lead at different periods during development. *ToxicolApplPharmacol*, 136:101-20.
 - 30) Ronis, M.J., Gandy, J. and Badger, T. (1998): Endocrine mechanisms underlying reproductive toxicology in the developing rat chronically exposed to dietary lead. *J. Toxicol. Environ. Health A.*, 54: 77-99.
 - 31) Shirota, M., Soda, S., Katoh, C., Asai, S., Sato, M., Ohta, R., Watanabe, G., Taya, K. and Shirota, K. (2003): Effects of reduction of the number of primordial follicles on follicular development to achieve puberty in female rats. *Reproduction, Jan*; 125(1): 85-94.
 - 32) McMurry, S.T., Lochmiller, R.L., Chandra, S.A. and Qualls, C.W. Jr(1995): Sensitivity of selected immunological, hematological and reproductive parameters ih the cotton rat (*Sigmodonhispidus*) to subchronic lead exposure. *J Wildl Dis, Apr*; 31(2): 193-204.
 - 33) Dennery, P.A. (2004): Role of redox in fetal development and neonatal diseases. *Antioxid Redox Signal*, 6: 147-153.
 - 34) Jacquet, P. (1978): Effect of exogenous progesterone and estradiol on the process of embryonic implantation in lead intoxicated female mice. *C.R. SeanesSocBiolFil.*, 172: 1037-1040.
 - 35) Wide, M. (1980): Interference of lead with implantation in the mouse: Effect of exogenous oestradiol and progesterone. *Teratology*, 21: 187-191.
 - 36) Agarwal, A., Gupta, S. and Sharma, R. K. (2005): Role of oxidative stress in female reproduction. *ReprodBiolEndocrinol*, Jul 14; 3(1):28.

- 37) Zingg, J. M. (2007): Vitamin E: An Overview of major research directions. *Mol. Aspects Med., Oct-Dec*; 28 (5-6): 400-422.
- 38) Evans, A.C.O., Komar, C.M., Wandji, S.A. and Fortune, J.E. (1997): Changes in androgen secretion and lutenizing hormone pulse amplitude are associated with the recruitment and growth of ovarian follicles during the luteal phase of the bovine estrous cycle. *BiolReprod*, 57,394-40.
- 39) Bedaiwy, M.A. and Falcone, T. (2003): Peritoneal fluid environment in endometriosis. Clinicopathological implications. *Minerva Ginecol*, 55: 333-345.
- 40) Balasch, J. and Fabregues, F. (2006): LH in the follicular phase: neither too high nor too low. *Reprod Biomed Online*, 12: 406-15.
- 41) Tajima, K., Orisaka, M., Mori, T. and Kotsuji, F. (2007): Ovarian theca cells in follicular function. *Reprod Biomed Online*, 15(4): 15: 591-609.
- 42) Mori, T., Nonogauchi, K., Watanabe, H., Ishikawa, H., Tamura, I. and Kinoshita, K. (2009): Morphogenesis of polycystic ovaries as assessed by pituitary ovarian androgenic function. *Reprod Biomed Online*, 18: 635-643.
- 43) Tilly, J. L. and Tilly, K. I. (1995): Inhibitors of oxidative stress mimic the ability of follicle stimulating hormone to suppress apoptosis in culture rat ovarian follicles. *Endocrinology*, 136: 242-252.
- 44) Luck, M.R., Jeyaseelan, I. and Scholes, R.A. (1995): Ascorbic acid and fertility. *BiolReprod*, Feb; 52(2): 262-6.
- 45) Kannan, G. M. and Flora, S.J. (2004): Chronic arsenic poisoning in the rat: treatment with combined administration of succimers and an antioxidant. *Ecotoxicol Environ Sef, May*; 58(1): 37-43.
- 46) Kim, S.S., Yang, H.W., Kang, H.G., Lee, H.H., Lee, H.C., Ko, D.S. and Gosden, R.G. (2004): Quantitative assessment of ischemic tissue damage in ovarian cortical tissue with or without antioxidant (ascorbic acid) treatment. *Fertile Steril, Sep.*, 82(3): 679-85.
- 47) Murray, A.A., Molinek, M.D., Baker, S.J., Kojima, F.N., Smith, M.F., Hillier, S.G. and Spears, N. (2001): Role of ascorbic acid in promoting follicle integrity and survival in intact mouse ovarian follicles in vitro. *Reproduction*, Jan; 121(1): 89-96.
- 48) Qureshi, N., Sharma, R., Mogra, S. and Panwar, K. (2010): Amelioration of lead induced alterations in ovary of Swiss mice, by antioxidant vitamins. *J Herbal Med Toxicol*, 4(1): 89-95.
- 49) Brigelius- Flohe, R., Kelly, F.J., Salonen, J.T., Neuzil, J., Zingg, J.M. and Azzi, A. (2002): The European perspective on vitamin E: current knowledge and future research. *Am J Clin Nutr*, Oct; 76(4): 703-13.
- 50) Stocker, R. and Frei, B. (1991): Endogenous antioxidant defenses in human blood plasma. In: *Oxidative Stress (Sies, H. ed.)* pp. 213-243. Academic Press, London.
- 51) Tariq, S.A. (2007): Role of Ascorbic Acid in Scavenging Free Radicals and Lead Toxicity from Biosystems. *MolBiotechnol*, 37:62-65.